

ORIGINAL ARTICLE

2012 European guideline for the management of anogenital warts

C.J.N. Lacey,^{†,*} S.C. Woodhall,[†] A. Wikstrom,[‡] J. Ross[§][†]Hull York Medical School, University of York, York, UK[‡]Department of Dermatovenereology, Karolinska Hospital, Stockholm, Sweden[§]Whittall Street Clinic, Birmingham, UK

*Correspondence: C.J.N. Lacey. E-mail: charles.lacey@hyms.ac.uk

Abstract

Background Although new HPV vaccines have been developed and are in the process of implementation, anogenital warts remain a very frequent problem in clinical practice.

Objective We wished to update previously published European guidelines for the management of anogenital warts.

Methods We performed a systematic review of randomized controlled trials for anogenital warts. The primary data were analyzed and collated, and the findings were formulated within the structure of a clinical guideline. The IUSTI Europe Editorial Board reviewed the draft guideline which was also posted on the web for comments which we incorporated into the final version of the guideline.

Results The data confirm that only surgical therapies have primary clearance rates approaching 100%. Recurrences, including new lesions at previously treated or new sites, occur after all therapies, and rates are often 20–30% or more. All therapies are associated with local skin reactions including itching, burning, erosions and pain.

Conclusions Physicians treating patients with genital warts should develop their own treatment algorithms which include local practice and recommendations. Such patient level management protocols should incorporate medical review of cases at least every 4 weeks, with switching of treatments if an inadequate response is observed. First episode patients should be offered sexually transmitted disease screening. Management should include partner notification and health promotion.

Received: 20 September 2011; Accepted: 1 February 2012

Conflicts of interest

CL has received consultancy fees from GSK & SPMSD. JR has received speaker's fees, sponsorship to attend conferences and research grants from Abbott, Boehringer Ingelheim, Gilead, GSK, Roche, BMS, MSD, Bayer and Tibotec.

Funding sources

None declared.

Aetiology and transmission

Anogenital warts (also known as genital warts, condylomata acuminata, condylomas) are benign proliferative lesions caused by human papillomavirus (HPV) types 6 and 11, which are found in >95% of lesions.^{1,2} Anogenital warts are often co-infected with 'high risk' HPVs such as HPV 16.² Genital warts are sexually transmitted, with transmission rates of ~60% between partners.³

This guideline has been produced on behalf of the following organizations: the European Branch of the International Union against Sexually Transmitted Infections (IUSTI Europe); the European Dermatology Federation (EDF); the Union of European Medical Specialists (UEMS).

Clinical features

Symptoms

Most patients only complain of the presence of the lesions, which are otherwise symptomless. However, symptoms can include itching, bleeding, fissuring or dyspareunia.

Physical signs

Lesions are often found in sites that are traumatized during intercourse and may be solitary, but frequently there will be 5–15 lesions of 1–5 mm diameter. Warts may coalesce into larger pla-

ques, and this is more commonly seen with immunosuppression and in diabetes. In uncircumcised men, the preputial cavity (glans penis, coronal sulcus, frenulum, inner aspect of the foreskin) is most commonly affected, while in circumcised men the shaft of the penis is often involved.⁴ Warts may also occur at the urethral meatus, pubis, scrotum, groin, perineum, perianal area and anal canal. In females, lesions occur at the fourchette, labia minora, labia majora, pubis, clitoris, urethral meatus, perineum, perianal region, anal canal, introitus, vagina and ectocervix. Intra-anal warts are most common when receptive anal intercourse has been practised, although also occur without such.⁵ Warts are very seldom found proximal to the dentate line. Anogenital warts can vary significantly in colour, from pink to salmon red, and from white to greyish white to various shades of brown (pigmented lesions). Warts tend to be non-pigmented, but pigmented lesions are mostly seen on the labia majora, penile shaft, pubis, groin, perineum and perianal area.

Complications

Physical and psychosexual implications Anogenital warts are frequently perceived as disfiguring and often impact sexual lifestyle. They cause feelings of anxiety, guilt, anger and loss of self esteem, and create concerns about future fertility and of cancer risk.^{6,7}

Pre-cancer and cancer Both premalignant (vulval, anal and penile intra-epithelial neoplasia, i.e. VIN, AIN and PIN) or invasive lesions (vulval, anal and penile cancer) can co-exist within anogenital wart lesions, can develop within existing genital warts, or be misdiagnosed as genital warts. Bowenoid papulosis (BP) are reddish-brown lesions associated with oncogenic HPV types, and are part of the clinical spectrum of anogenital intraepithelial neoplasia. Clinical suspicion of neoplastic change should be aroused by bleeding, irregular and unusual patterns of pigmentation, ulceration, or lesions with palpable dermal infiltration. Urgent biopsy or appropriate specialist referral must be considered. Another rare variant of HPV 6/11 disease is the giant condyloma or Buschke-Lowenstein tumour. This is a form of verrucous carcinoma, characterized by aggressive local infiltration into underlying dermal structures. Management requires specialist surgical and oncological referral, with recent reports suggesting good outcomes with chemo-radiotherapy.⁸

Diagnosis – key points

- Examine with a good light; a lens or colposcope may be useful for small lesions.
- In men, always examine the meatus, and have a low threshold for examining the perianal area and performing proctoscopy to examine the anal canal. In women, always examine the perianal area and perform a speculum examination to exclude cervical or vaginal lesions, and have a low threshold

for performing proctoscopy to examine the anal canal. Proctoscopy is safe in subjects with perianal warts.

- Biopsy is not necessary for typical anogenital warts; biopsy must always be performed if there is any suspicion of pre-cancer or cancer, and can be useful for differential diagnosis
- Not all papular lesions are caused by HPV. Always consider normal variants such as pearly penile papules and Fordyce spots and differential diagnoses such as molluscum contagiosum, seborrheic keratoses, etc.
- HPV typing of anogenital warts does not add information of clinical use, and is not recommended
- Some practitioners use the acetic acid test to diagnose sub-clinical HPV lesions; its place in diagnosis and management remains controversial.

Management

In the formulation of these guidelines we have reviewed and considered those produced recently by national groups in the United Kingdom and United States.^{9,10} We have also evaluated the evidence that supports our treatment recommendations using grades developed by the Agency for Health Care Policy and Research (see Table 1).¹¹

Not all therapeutic preparations for genital warts are available in all countries. Therefore, in this guideline we have limited our review and recommended therapies to those therapies available in Europe, and have indicated where any therapy is only available in certain countries.

Information, explanation and advice for the patient

- Patients should be given a detailed explanation of their condition. This should be reinforced by offering them clear and accurate written information. Useful patient oriented resources are available via the CDC <http://www.cdc.gov/std/hpv> and ASHA <http://www.ashastd.org/std-sti/hpv.html> websites (IV; C).

Therapy

Currently available treatments We carried out a systematic review of randomized controlled trials (RCTs) of treatments for genital warts (Woodhall SC, Lacey CJ, unpublished data). Previous systematic reviews and RCTs were identified and the primary data obtained, analyzed and collated (see Search strategy). Some of the results are presented in Table 2. The data confirms that only surgical therapies have primary clearance rates approaching 100%, and that recurrences occur after all therapies. Recurrence rates, including new lesions at previously treated or new sites, are often 20–30% or more. All therapies are associated with local skin reactions including itching, burning, erosions and pain. Within these caveats, our recommended treatment modalities are:

Table 1 Levels of evidence and grading of recommendations¹¹

Level	Type of evidence
Ia	Evidence obtained from meta-analysis of randomized controlled trials
Ib	Evidence obtained from at least one RCT
IIa	Evidence obtained from at least one well designed controlled study without randomization
IIb	Evidence obtained from at least one other type of well designed quasi-experimental study
III	Evidence obtained from well designed non-experimental descriptive studies, such as comparative studies, correlation studies and case-control studies
IV	Evidence obtained from expert committee reports or opinions and/or clinical experience of respected authorities
Grade	Recommendation
A (evidence levels Ia, Ib)	Requires at least one RCT as part of a body of literature of overall good quality and consistency addressing the specific recommendation
B (evidence levels IIa, IIb, III)	Requires availability of well conducted clinical studies but no RCTs on the topic of recommendation
C (evidence level IV)	Requires evidence from expert committee reports or opinions and/or clinical experience of respected authorities. Indicates absence of directly applicable studies of good quality

RCT, randomized controlled trial.

Home therapy

- Podophyllotoxin (0.15% cream or 0.5% solution)
- Imiquimod (5% cream)
- Sinecatechins (10% ointment)

Clinic therapy

- Cryotherapy
- Trichloroacetic acid
- Electrosurgery/scissors excision/curettage/laser

Home therapy.

1. *Podophyllotoxin 0.5% solution and 0.15% cream (Ib, A)*. Each course of podophyllotoxin treatment comprises self application twice daily for 3 days, followed by four rest days. Use of 0.5% podophyllotoxin solution is convenient for penile warts. However, vulvar and anal warts are more feasibly and efficiently treated with 0.15% podophyllotoxin cream, when inspection, often aided by a mirror and digital palpation, facilitate the application procedure.

Clearance rates of 45–83% after use of 0.5% podophyllotoxin solution for 3–6 weeks have been reported.^{12–20} Efficacy with use of podophyllotoxin solution is probably lower in females and circumcised males. Clearance rates of 43–70% have been reported after the use of 0.15% podophyllotoxin cream at 4 weeks.^{15–17} Meatal warts and warts on keratinized skin are often refractory.¹²

Up to 65% of patients using podophyllotoxin experience transient and acceptable burning, tenderness, erythema and/or erosions for a few days when the warts necrotize.^{14,15} Recurrence rates of 6–100% have been reported with podophyllotoxin preparations between 8 and 21 weeks after clearance.^{12–15,17,18}

Podophyllotoxin is contraindicated during pregnancy, and women of childbearing age must use contraception or abstain from penetrative sexual activity during therapy.

2. *Imiquimod cream 5% (Ib, A)*. Imiquimod cream is supplied as a package of twelve single use sachets. It is applied to the warts three times a week at bedtime and the area washed with soap and water the next morning. Treatment continues until wart clearance, or for a maximum of 16 weeks. Local reactions at the treatment site may occur and these can be managed by a rest period of several days, or by reducing the frequency of application.

In clinical studies, wart clearance has been reported in 35–68% of patients with treatment courses up to 16 weeks.^{20–27} The reported clearance rates are higher in women than in men, and also women have a shorter median time to clearance than men.

Erythema is often seen as a side effect with imiquimod therapy, and sometimes appears to precede clinical resolution. Occasionally severe inflammation is seen necessitating discontinuation of therapy. Phimosis and lichen sclerosis after therapy have also been reported. Relatively low recurrence rates (6–26%) after successful clearance have been reported.^{22,23,26,27}

Animal studies with imiquimod have not revealed any teratogenic effects in rats and rabbits. No adverse effects were found on reproduction in a second generation rat study. Two case series of imiquimod use in pregnant women have been published, and no adverse pregnancy outcomes or foetal abnormalities have been reported.^{28,29} Nevertheless, more data is needed before imiquimod cream can be considered safe during pregnancy.

3. *Sinecatechins (Veregen® 10% ointment) (Ib, A)*. Veregen® (CPM Contract Pharma GmbH & Co., Feldkirchen-Westerham, Germany) is currently available in the United States, Germany and Austria. It is marketed as a 10% ointment in Europe and a 15% ointment in the US. A marketing approval process for 17 further European countries has been initiated and more widespread availability is expected by end-2012. Veregen® is a preparation of green tea catechins (sinecatechins) with the principal component epigallocatechin gallate (EGCG). Evidence suggests the mechanism of action of EGCG is through anti-proliferative mechanisms. The ointment is applied three times a day until complete clearance, or for up to 16 weeks. It cannot be used internally or in pregnancy.

Three double-blind placebo-controlled RCTs have been published, and a synthesis with further details of two of the trials.^{30,31} Clearance rates of 47–59% over 12–16 weeks were seen with sinecatechin ointment. There did not appear to be any difference in response rates between 10% and 15% ointment.³¹ Local side effects were seen as frequently as with other topical therapies. In those clearing, low recurrence rates of 7–11% were observed over 12 weeks follow up.

Table 2 Randomized controlled trials of therapies for anogenital warts among HIV negative patients (lb, A)

Treatment/intervention	Treatment schedule	Clearance rates ITT* (range)	Clearance rates PP† (range)	Clearance rates reported at:‡	Recurrence rates (range)§	Recurrence rates reported at:
Podophylotoxin solution 0.5% ¹²⁻²⁰	Twice a day for 3 days followed by 4 days break. 2-6 weeks treatment	45-83%	55-83%	3-6 weeks	13-100% ^{12-14,18}	8-21 weeks from end of treatment
Podophylotoxin cream 0.15% ¹⁵⁻¹⁷	Twice a day for 3 days followed by 4 days break. Maximum 4 weeks treatment	43-70%	43-70%	4 weeks	6-55% ^{15,17}	8-12 weeks from end of treatment
Imiquimod 5% cream ²⁰⁻²⁷	Three times per week	35-68%	55-81%	16 weeks	6-26% ^{21,22,25,26}	10 weeks to 6 months from end of treatment
Sinecatechins 10% & 15% ointment ^{30,31}	Three times a day for 12-16 weeks	47-59%	50-58%	12-16 weeks	7-11% ^{30,31}	12 weeks from clearance
Cryotherapy ³²⁻³⁶	6-10 weeks of treatment	44-75%	67-92%	6-10 weeks	21-42% ³⁰⁻³⁴	1-3 months from end of treatment
TCA ^{33,35}	One application per week for a maximum of 8-10 weeks	56-81%	81-84%	8-10 weeks	36% ³¹	2 months post-treatment
Electrosurgery ^{32,37}	One to six treatment sessions (median 1)	94-100%	94-100%	1-6 weeks	22% ³⁰	3 months from end of treatment
Scissors excision ^{38,40}	One or two excision sessions	89-100%	89-100%	6 weeks	19-29% ³⁶⁻³⁸	10-12 months from baseline

*Note that clearance rates and recurrence rates are not directly comparable as clearance was measured at different times from the start of treatment and high loss to follow up was often experienced in the trials.

†All clearance rates are based on conservative estimates of efficacy, where by the ITT population was included in each case. The number enrolled into each group was taken as the denominator and the number known to have cleared as the numerator. This assumes that for any missing data, participants were assumed not to be cleared.

‡Clearance rates based on the non-missing data (PP). The number with evaluable follow up data was taken as the denominator and the number known to have cleared as the numerator.

§Recurrence rates are based on the recurrences observed among those available for follow up who had originally experienced clearance. Several trials experienced high loss to follow up rates, so recurrence rates should be interpreted with caution.

ITT, intent to treat; PP, per protocol; TCA, trichloroacetic acid.

Office therapy

1. *Cryotherapy (Ib, A)*. Cryotherapy can be delivered by 'open' (liquid nitrogen) or 'closed' systems. Open application of liquid nitrogen is usually delivered by spray gun device, freezing the lesion and a margin of healthy skin for about 20 s. Closed cryo-probe systems utilize circulation of nitrous oxide or carbon dioxide, the probe gently pressed to the surface moistened with saline or lubricating jelly and freezing performed until a freezing 'halo' occurs a few millimetres around the lesion. A freeze-thaw-freeze technique is applied to each lesion at each session. Application techniques are difficult to standardize and there may be significant intra-operator differences. Cryotherapy is usually performed at weekly intervals, although no studies have systematically evaluated different treatment intervals.

Cryotherapy has the advantages of being simple, inexpensive, rarely causes scarring or depigmentation, and is safe in pregnancy. Clinical studies have reported clearance rates in the range of 44–75%,^{32–35} and recurrence rates of 21–42% one to three months after clearance.^{32–34}

2. *Trichloroacetic acid (TCA) 80–90% solution (Ib, A)*. TCA is a caustic agent. It is applied sparingly directly to the wart surface with either the wooden or a cotton tip end of an applicator, as per preference, and is usually applied weekly. It is most suitable for small acuminate or papular warts but less easy to use on keratinized or large lesions. TCA is corrosive and overzealous use may cause scarring. A neutralising agent (for example, sodium bicarbonate) should be readily available in case of excess application or spills. When used optimally, a shallow ulcer forms that heals without scarring. Response rates of 56–81% have been reported,^{33,35} with recurrence rates of 36%.³³ TCA can be used safely during pregnancy.

3. *Surgical treatment*. A variety of surgical techniques are in use, including electro-surgery, curettage, scissors excision and laser therapy. Surgery may be used as primary therapy, and the majority of patients can be treated under local anaesthesia. Routine use of local anaesthetic cream is recommended before infiltration anaesthesia, reducing discomfort from injections significantly. Use of up to 100 mg lidocaine, as 5 mL of 2% or 10 mL of 1%, for infiltration gives rapid anaesthesia of the epithelium. Adrenaline as adjuvant reduces bleeding but is contraindicated on the penis and in the clitoris region, and clinics therefore may choose not to stock the combined preparations to prevent inadvertent inappropriate use. When performed carefully, simple surgical approaches leave highly satisfactory cosmetic results.

(a) *Electrosurgery (Ib, A) scissors excision (Ib, A), curettage and laser surgery (IIa, B)*. Modern electro-surgical units utilize alternating current to produce different types of wave forms resulting in blends of cutting and coagulation. These systems use isolated circuitry, can be monopolar or bipolar, and vary from small simple devices to larger complex systems. Scissors excision is useful when

smaller numbers of lesions are present and may be assisted by diathermy to control bleeding and to destroy any conspicuous wart tissue remaining after the excision. Clearance rates of 94–100% and 89–100% have been reported for electro-surgery and scissors excision, respectively, with recurrence rates of 19–29%.^{32,37–40}

Curettage is a simple effective technique for small numbers of lesions, and either diathermy or silver nitrate is used for haemostasis. Carbon dioxide and YAG laser emissions result in very high power densities being delivered to small tissue volumes. Both electro-surgery and laser surgery should be performed with the use of surgical masks by the treatment team, and the use of a smoke evacuator. We were not able to locate any suitable RCTs evaluating curettage or laser therapy.

(b) *Formal surgery (IVc)* – bulky warts, extensive warts, anal/intra-anal warts and significant lesions in children are most conveniently removed under general anaesthesia by an appropriate surgical specialist.

Therapies not generally recommended

Routine use of podophyllin or interferons is not recommended. Podophyllin 20–25%, a non-standardized resin extract from the *Podophyllum* plant, is inexpensive to produce but is associated with only moderate efficacy. However, up to 10% of podophyllin contains the mutagenic compounds quercetin and kaempferol,⁴¹ and severe systemic toxicity after topical use has been described, including death, intrauterine death, teratogenicity and various neurological complications.⁴² In the specialist setting, α - and β -interferons are sometimes used as adjuvants to surgery in problem cases, and a recent systematic review supported the use of topical or intralesional interferon.⁴³ Combination therapies are also not infrequently used in clinical practice,³⁵ and further evaluation of such therapies is warranted.³⁶

Treatment algorithms Clinicians who treat patients with genital warts should have access to a range of home and clinic-based therapies. Choice of therapy depends on the morphology and extent of warts and should be made by mutual agreement between the physician and the patient. Patients with limited disease (1–5 warts) will often opt for immediate therapy in clinic. As warts regress spontaneously in some patients, no treatment is an option for warts at any site. A simple treatment algorithm is illustrated in Fig. 1.

Vaginal, cervical, intra-meatal, intra-anal warts Vaginal warts can be treated with either TCA or cryotherapy. Cervical warts should be managed by a gynaecologist. Intra-meatal warts can be treated with either TCA or various surgical techniques. TCA can be used for small volume intra-anal warts, and imiquimod use is feasible with suitable patient motivation. Otherwise formal surgical referral is indicated for intra-anal warts (see above).

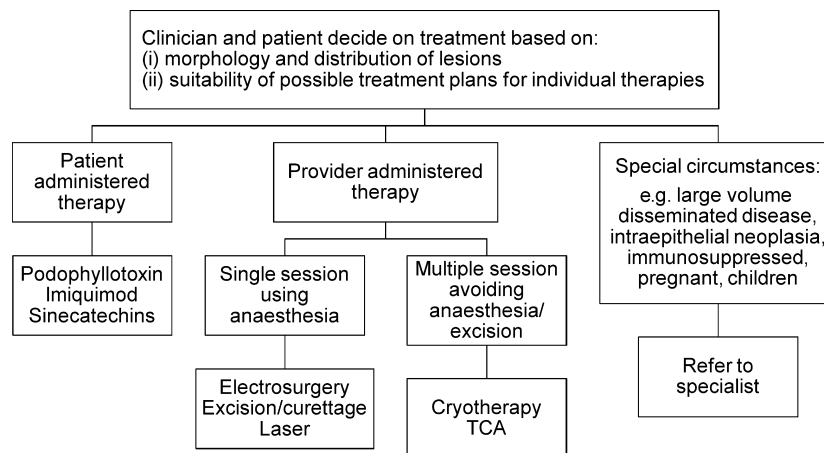


Figure 1 Algorithm for the treatment of external anogenital warts.

Treatment in pregnancy In pregnancy warts may enlarge and multiply. Genital warts present at delivery are associated with a risk of ~1 in 400 of the infant developing juvenile laryngeal papillomatosis.⁴⁴ There is no proof that treatment diminishes this risk, although reduction of viral burden would seem wise. Liaison with the obstetrician in management is recommended. Spontaneous regression of genital warts is very frequently seen in the puerperium.

Treatment in immunocompromised patients Both HIV infection and iatrogenic immunosuppression are associated with an increased prevalence of anogenital warts. Furthermore, the response to treatment in HIV positive subjects is impaired, and recurrences after treatment are more common.^{45,46} Recent studies of the use of imiquimod in patients treated with HAART showed total clearance rates of 31–32%,^{45,47} whereas an RCT of surgery combined with imiquimod demonstrated a 100% primary clearance.⁴⁶

Partner notification

- Current partners and, if possible, other partners within the past 6 months, should be assessed for the presence of lesions and for education and counselling about STDs and their prevention.
- Condoms have been shown to protect against the acquisition of genital warts.^{48,49} Analyses of whether condoms protect against HPV transmission *per se* are more complex with mixed results,⁴⁹ but recent data suggests that male condom use may protect females against HPV acquisition.^{50,51} Condom use has also been shown to accelerate disease resolution when both partners have type-concordant HPV infection.^{52–54} Therefore condom use is recommended within partnerships when either subject has genital warts until resolution of lesions (Ib; A).

Follow up

- It is good practice for units treating patients with genital warts to develop their own treatment algorithms including local practice and recommendations. Such patient level management protocols should incorporate medical review of cases at least every 4 weeks, with switching of treatments if an inadequate response is observed. Implementation of such treatment algorithms has been shown to result in improved outcomes.⁵⁵

Prevention/health promotion

- Genital warts are commoner in smokers, and smoking behaviour is correlated with sexual behaviour, increased numbers of sexual partners, and adverse reproductive sequelae.^{56,57} Although there is no evidence at present that smoking cessation improves the outcome of treatment for genital warts, there is a clear individual and public health rationale for advising smoking cessation. (IV; C).
- Patients with first episode genital warts should be offered sexually transmitted disease screening as per local guidelines. (III, IV; C).
- Female patients should be informed about cervical cytology screening as per local/national guidelines. Recommendations in the UK are that women with genital warts should be screened according to standard guidelines.

Search strategy

A scoping search of existing systematic reviews of genital warts treatments was carried out by searching the Cochrane Database of Systematic Reviews, MEDLINE and EMBASE. Searches were carried out in MEDLINE, EMBASE and the Cochrane library (including Cochrane Database of Systematic Reviews, Database of Abstracts of Reviews and Effects and Cochrane Central Register of Controlled Trials) according to a pre-defined search strategy (see Table 3). Randomized controlled trials (RCTs) of provider-admin-

Table 3 Search strategy

Combine with AND search	
Population (Combine with OR search)	
Keywords:	
Genital wart	
Anogenital wart	
Ano-genital wart	
Ano genital wart	
Anal wart	
Condyloma	
Venereal wart	
Plus appropriate mapped/MeSH headings	
Intervention (Combine with OR search)	
Keywords:	Excision
Podophyllotoxin	Surgical removal
Podofilox	Laser
Podophyllin	Electrosurgery
Cryotherapy	Electrocautery
Liquid nitrogen	Hyfrecation
Imiquimod	Ablati
Aldara	Diathermy
TCA	Interferon
Trichloroacetic acid	5-fluorouracil
BCA	Polyphenon
Bichloroacetic acid	Photodynamic
Curettage	Tretin (to capture acitretin, tretinoin, isotretinoin)
	Retinoids
Plus appropriate mapped/MeSH headings	

In addition, filters described in the Cochrane Handbook of Systematic Reviews (<http://www.cochrane-handbook.org>) were applied to limit the searches to RCTs.

BCA, bichloroacetic acid; TCA, trichloroacetic acid.

istered or prescribed therapies for anogenital warts were eligible for inclusion where participants were 16 years old or over; the warts had been clinically diagnosed and clearance or recurrence rates were reported as an outcome measure. The search was restricted to English-language publications and all databases were searched up to March 2011.

Study selection was a two stage process; abstracts and titles were reviewed and full papers were then obtained for any papers which potentially met the eligibility criteria, at which point the eligibility criteria were applied to the full manuscript. The reference lists of the included papers were hand searched to identify other potentially eligible papers. Due to resource constraints, while the initial electronic search and identification of papers was carried out by two reviewers, the final decision about eligibility was carried out by a single reviewer. Data extraction was carried out using a piloted data extraction template. Data extraction was carried out by one reviewer, with a sample of ~10% of papers being double checked for accuracy by another reviewer. Study quality was deter-

mined by applying the Cochrane Collaboration's tool for assessing risk of bias (available from: <http://www.cochrane-handbook.org>).

Composition of the IUSTI Europe Editorial Board

Keith Radcliffe (Editor-in-Chief), Marita van de Laar, Michel Janier, Jorgen Skov Jensen, Martino Neumann, Raj Patel, Jonathan Ross, Willem van der Meijden, Harald Moi, Jackie Sherrard, Magnus Unemo, Karen Babayan, Angela Robinson, James Bingham, Mikhail Gomberg, Marco Cusini.

References

- Meyer T, Arndt R, Christophers E *et al.* Association of rare human papillomavirus types with genital premalignant and malignant lesions. *J Infect Dis* 1998; **178**: 252–255.
- Brown DR, Schroeder JM, Bryan JM, Stoler MH, Fife KH. Detection of multiple human papillomavirus types in condylomata acuminata lesions from otherwise healthy and immunosuppressed patients. *J Clin Microbiol* 1999; **37**: 3316–3322.
- Oriel JD. Natural history of genital warts. *Br J Vener Dis* 1971; **47**: 1–13.
- Cook LS, Koutsky LA, Holmes KK. Clinical presentation of genital warts among circumcised and uncircumcised heterosexual men attending an urban STD clinic. *Genitourin Med* 1993; **69**: 262–264.
- Sonnex C, Schofield JH, Kocjan G *et al.* Anal human papillomavirus infection in heterosexuals with genital warts: prevalence and relation with sexual behaviour. *Brit Med J* 1991; **303**: 1243.
- Woodhall S, Ramsey T, Cai C *et al.* Estimation of the impact of genital warts on health-related quality of life. *Sex Transm Inf* 2008; **84**: 161–166.
- Maw RD, Reitano M, Roy M. An international survey of patients with genital warts; perceptions regarding treatment and impact on lifestyle. *Int J STD AID* 1998; **9**: 571–578.
- Armstrong N, Foley G, Wilson J, Finan P, Sebag-Montefiore D. Successful treatment of a large Buschke-Lowenstein tumour with chemoradiotherapy. *Int J STD AIDS* 2009; **20**: 732–734.
- Clinical Effectiveness Group (British Association for Sexual Health and HIV). United Kingdom National Guideline for the Management of Anogenital Warts, 2007. URL <http://www.bashh.org/documents/86/86.pdf> (Last accessed 27 February 2012).
- Centers for Disease Control and Prevention. Sexually Transmitted Diseases Treatment Guidelines, 2010. MMWR 2010;59(No. RR-12): URL <http://www.cdc.gov/std/treatment/2010/genital-warts.htm> (Last accessed 27 February 2012).
- US Department of Health and Human Services, Agency for Health Care Policy and Research. Acute pain management: operative or medical procedures and trauma. ClinicalPracticeGuidelinesNo1. AHCPR, Rockville, MD. Publication No 92-0023, 1993:107.
- Von Krogh G, Szpak E, Andersson M *et al.* Self-treatment using 0.25–0.5% podophyllotoxin ethanol solutions against penile condylomata acuminata – a placebo-controlled comparative study. *Genitourin Med* 1994; **70**: 105–109.
- Beutner KR, Conant MA, Friedman-Kien A. Patient-applied podofilox for treatment of genital warts. *Lancet* 1989;**i**:831–834.
- Kirby P, Dunne A, King DH, Corey L. Double-blind randomized clinical trial of self-administered podofilox solution versus vehicle in the treatment of genital warts. *Am J Med* 1990; **88**: 465–470.
- Claesson U, Lassus A, Happonen H *et al.* Topical treatment of venereal warts: a comparative open study of podophyllotoxin cream versus solution. *Int J STD AIDS* 1996; **7**: 429–434.
- Strand A, Brinkeborn R-M, Siboulet A. Topical treatment of genital warts in men, an open study of podophyllotoxin cream compared with solution. *Genitourin Med* 1995; **7**: 387–390.

- 17 Lacey CJ, Goodall RL, Tennvall GR *et al*. Randomised controlled trial and economic evaluation of podophyllotoxin solution, podophyllotoxin cream, and podophyllin in the treatment of genital warts. *Sex Transm Infect* 2003; **79**: 270–275.
- 18 Edwards A, Atma RA., T R.N. Podophyllotoxin 0.5% v podophyllin 20% to treat penile warts. *Genitourin Med* 1988; **64**: 263–265.
- 19 Mazurkiewicz W, Jablonska S. Clinical efficacy of condylina (0.5% podophyllotoxin) solution and cream versus podophyllin in the treatment of external condylomata acuminata. *J Dermatol Treat* 1990; **1**: 123–125.
- 20 Komericki P, Akkilic-Materna M, Strimitzer T, Aberer W. Efficacy and safety of imiquimod versus podophyllotoxin in the treatment of genital warts. *Sex Transm Dis* 2011; **38**: 216–218.
- 21 Beutner KR, Tying SK, Trofatter KF Jr *et al*. Imiquimod, a patient-applied immune-response modifier for treatment of external genital warts. *Antimicrob Agents Chemother* 1998; **42**: 789–794.
- 22 Beutner KR, Spruance SL, Hougham AJ, Fox TL, Owens ML, Douglas JM Jr. Treatment of genital warts with an immune-response modifier (imiquimod). *J Am Acad Dermatol* 1998; **38**: 230–239.
- 23 Edwards L, Ferenczy A, Eron L *et al*. Self-administered topical 5% imiquimod cream for external anogenital warts. *Arch Dermatol* 1998; **134**: 25–30.
- 24 Fife KH, Ferenczy A, Douglas JM Jr *et al*. Treatment of external genital warts in men using 5% imiquimod cream applied three times a week, once daily, twice daily, or three times a day. *Sex Transm Dis* 2001; **28**: 226–231.
- 25 Garland SM, Waddell R, Mindel A, Denham IM, McCloskey JC. An open-label phase II pilot study investigating the optimal duration of imiquimod 5% cream for the treatment of external genital warts in women. *Int J STD AIDS* 2006; **17**: 448–452.
- 26 Schofer H, Van Ophoven A, Henke U, Lenz T, Eul A. Randomized, comparative trial on the sustained efficacy of topical imiquimod 5% cream versus conventional ablative methods in external anogenital warts. *Eur J Dermatol* 2006; **16**: 642–648.
- 27 Arican O, Guneri F, Bilgic K, Karaoglu A. Topical imiquimod 5% cream in external anogenital warts: a randomized, double-blind, placebo-controlled study. *J Dermatol* 2004; **31**: 627–631.
- 28 Einarson E, Costei A, Kalra S, Rouleau M, Koren M. The use of topical 5% imiquimod during pregnancy: a case series. *Reprod Toxicol* 2006; **21**: 1–2.
- 29 Audisio T, Roca FC, Piatti C. Topical imiquimod therapy for external anogenital warts in pregnant women. *Int J Gynaecol Obstet* 2008; **100**: 275–276.
- 30 Gross G, Meyer KG, Pres H, Thielert C, Tawfik H, Mescheder A. A randomized, double-blind, four-arm parallel-group, placebo-controlled Phase II/III study to investigate the clinical efficacy of two galenic formulations of Polyphenon E in the treatment of external genital warts. *J Eur Acad Dermatol Venereol* 2007; **21**: 1404–1412.
- 31 Tatti S, Stockfleth E, Beutner KR *et al*. Polyphenon E[®]: a new treatment for external anogenital warts. *Br J Dermatol* 2010; **162**: 176–184.
- 32 Stone KM, Becker TM, Hagdu A *et al*. Treatment of external genital warts: a randomised clinical trial comparing podophyllin, cryotherapy and electrodesiccation. *Genitourin Med* 1990; **66**: 16–19.
- 33 Godley MJ, Bradbeer CS, Gellan M *et al*. Cryotherapy compared with trichloroacetic acid in treating genital warts. *Genitourin Med* 1987; **63**: 390–392.
- 34 Handley JM, Maw RD, Horner T, Lawther H, McNeill T, Dinsmore WW. Non-specific immunity in patients with primary anogenital warts treated with interferon alpha plus cryotherapy or cryotherapy alone. *Acta Dermato-Venerologica* 1992; **72**: 39–40.
- 35 Sherrard J, Riddell L. Comparison of the effectiveness of commonly used clinic-based treatments for external genital warts. *Int J STD AIDS* 2007; **18**: 365–368.
- 36 Gilson RJ, Ross J, Maw R, Rowen D, Sonnex C, Lacey CJ. A multicentre, randomised, double-blind, placebo controlled study of cryotherapy versus cryotherapy and podophyllotoxin cream as treatment for external anogenital warts. *Sex Transm Inf* 2009; **85**: 514–519.
- 37 Panici PB, Scambia G, Baiocchi G, Perrone L, Pintus C, Mancuso S. Randomized clinical trial comparing systemic interferon with diathermocoagulation in primary multiple and widespread anogenital condyloma. *Obstet Gynecol* 1989; **74**: 393–397.
- 38 Jensen SL. Comparison of podophyllin application with simple excision in clearance and recurrences of perianal condylomata acuminata. *Lancet* 1985; **ii**: 1146–1148.
- 39 Khawaja HT. Treatment of condyloma acuminatum. *Lancet* 1986; **i**: 208–209.
- 40 Khawaja HT. Podophyllin versus scissor excision in the treatment of perianal condylomata acuminata: a prospective study. *Brit J Surg* 1989; **76**: 1067–1068.
- 41 Petersen CS, Weismann K. Quercetin and kaempferol: an argument against the use of podophyllin? *Genitourin Med* 1995; **71**: 92–93.
- 42 Lacey CJN. Therapy for genital human papillomavirus-related disease. *J Clin Virol* 2005; **32S**: S82–S90.
- 43 Yang J, Pu Y, Zeng Z, Yu Z, Huang N, Deng Q. Interferons for the treatment of genital warts: a systematic review. *BMC Infect Dis* 2009; **9**: 156.
- 44 Kashima HK, Shah K. Recurrent respiratory papillomatosis: clinical overview and management principles. *Obstet Gynecol Clin North Am* 1987; **14**: 581–588.
- 45 Cusini M, Salmaso F, Zerboni R *et al*. 5% imiquimod cream for external anogenital warts in HIV-infected patients under HAART therapy. *Int J STD AIDS* 2004; **15**: 17–20.
- 46 Viazis N, Vlachogiannakos J, Vasiliadis K, Theodoropoulos I, Saveriadis A, Karamanolis DG. Earlier eradication of intra-anal warts with argon plasma coagulator combined with imiquimod cream compared with argon plasma laser alone: a prospective, randomised trial. *Dis Colon Rectum* 2007; **50**: 2173–2179.
- 47 Saia P, Bauhofer A, Bouscarat F *et al*. Imiquimod 5% cream for external genital or perianal warts in human immunodeficiency virus-positive patients treated with highly active antiretroviral therapy: an open-label, noncomparitive study. *Br J Dermatol* 2009; **161**: 904–909.
- 48 Wen LM, Estcourt CS, Simpson JM, Mindel A. Risk factors for the acquisition of warts: are condoms protective? *Sex Transm Inf* 1999; **75**: 312–316.
- 49 Manhart LE, Koutsky LA. Do condoms prevent genital HPV infection, external genital warts, or cervical neoplasia? *A meta-analysis. Sex Transm Dis* 2002; **29**: 725–735.
- 50 Winer RL, Hughes JP, Feng Q *et al*. Condom use and the risk of genital human papillomavirus infection in young women. *N Engl J Med* 2006; **354**: 2645–2654.
- 51 Burchell A, Tellier P-P, Coutlee F, Hanley J, Franco E. Evidence for a protective effect of condoms against male-to-female transmission. 26th International Papillomavirus Conference, Montreal, 2010, Abstract P-622
- 52 Hogewoning CJ, Bleeker MC, van den Brule AJ *et al*. Condom use promotes regression of cervical intraepithelial neoplasia and clearance of human papillomavirus: a randomized clinical trial. *Int J Cancer* 2003; **107**: 811–816.
- 53 Bleeker MC, Hogewoning CJ, Voorhorst FJ *et al*. Condom use promotes regression of human papillomavirus-associated penile lesions in male sexual partners of women with cervical intraepithelial neoplasia. *Int J Cancer* 2003; **107**: 804–810.
- 54 Bleeker MC, Berkhof J, Hogewoning CJ *et al*. HPV type concordance in sexual couples determines the effect of condoms on regression of flat penile lesions. *Br J Cancer* 2005; **92**: 1388–1392.
- 55 Reynolds M, Fraser PA, Lacey CJN. Audits of the treatment of genital warts: closing the feedback loop. *Int J STD AIDS* 1996; **7**: 347–352.
- 56 Kjaer SK, Tran TN, Sørensen P *et al*. The burden of genital warts: a study of nearly 70,000 women from the general female population in the 4 Nordic countries. *J Infect Dis* 2007; **196**: 1447–1454.
- 57 Hansen BT, Kjaer SK, Munk C *et al*. Early smoking initiation, sexual behaviour and reproductive health – a large population-based study of Nordic women. *Prev Med* 2010; **51**: 68–72.